

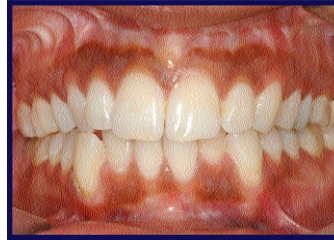
# Pretreatment/Case Planning Photo Checklist

To assist you in treatment planning, we need your insights through photographs. We have listed a number of views necessary to give you our best.



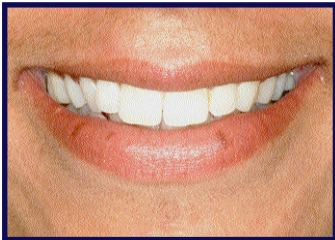## 1. Full face smiling

- have patient sit upright or stand
- pictures should be taken at a right angle, with patient's head straight
- smile should be natural not forced



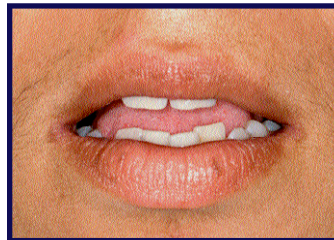
## 6. Maximum Intercuspation with retractors

- shows front-to-back progression



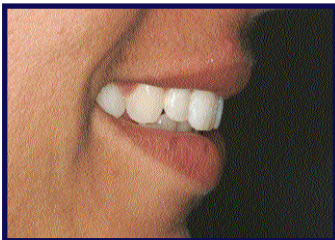
## 2. Smile - without retractors

- frame the image just inside nose-to chin; captures relationship of upper smile line to lower lip line



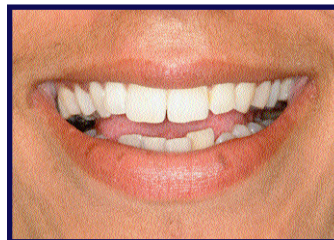## 7. Rest position

- to show display relationship of incisal plane of lower teeth to lower lip
- very important image to evaluate wear cases



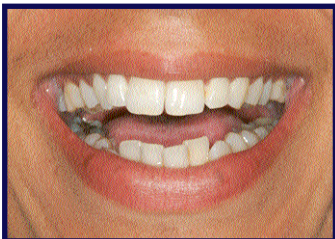
## 3. Profile - close-up

- shows the upper incisal edge position to inner vermillion border of lower lip



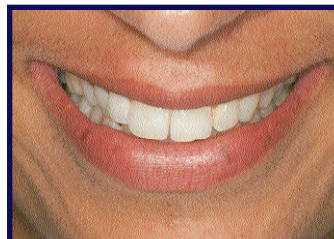
## 8. Smile - teeth apart

- displays the silhouette of upper and lower incisal plane



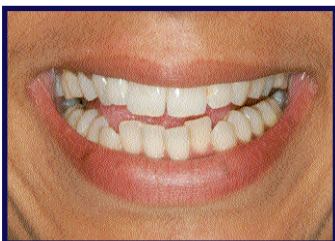
## 4. High smile line

- have patient laugh or smile as high as possible to determine maximum tooth display
- provides information on embrasures, symmetry of gingival heights, & information for margin placement



## 9. Smile - head tipped down slightly (with patient sitting, shoot down from above)

- shows the relationship of arch form to lower lip
- especially good for reviewing anterior pontics



## 5. "E" position

- shows relationship of upper incisors to upper lip
- age appropriate tooth wear may be evaluated



*In cases with severe wear, request an old photo from high school, college, or a wedding.*